

## Mass dolphin deaths in Peru caused by acoustic trauma

Posted May 17, 2012 by [Candace Calloway Whiting](#)

**Dr. Carlos Yaipen Llanos of ORCA in Peru informed Hardy Jones of Blue Voice that acoustical trauma is the cause of the Mass Mortality Event (MME) that killed an estimated one thousand dolphins along the coast of northern Peru in March 2012.**

In her article, [Hundreds of dead dolphins wash up along the coastline in Peru](#), Elizabeth Batt describes the devastating loss of the dolphins and porpoises, and the swift action by filmmaker and author Hardy Jones to document the event.

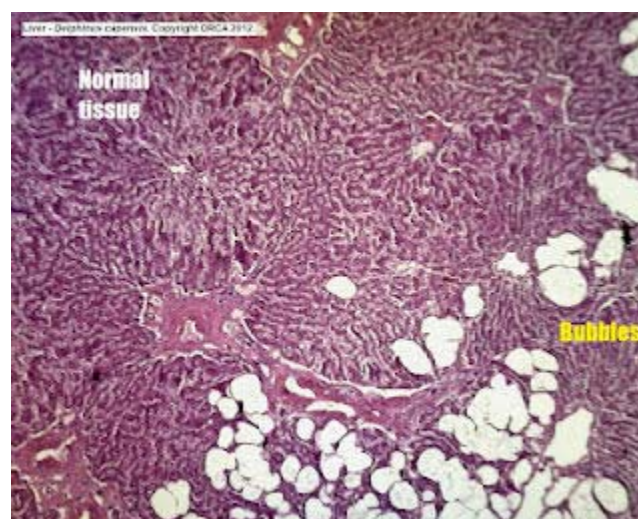
Now the necropsy results are in, and there is unequivocal evidence that the dolphins were killed by an acoustic trauma, such as loud sonar or explosive blasts (more information on potential sources of the loud sound in that region can be found [here](#)). Dr. Llanos doesn't identify the source of the trauma, but all other tests (virus, contaminants, parasites etc) are not considered factors.

The [following tissue samples](#), provided to Blue voice by Dr. Llanos show evidence of rapid ascent, (though the scientists are not willing to speculate on what caused the dolphins to race to the surface, their bodies are adapted to adjust to depth, and normally do not aggregate bubbles in their tissues).



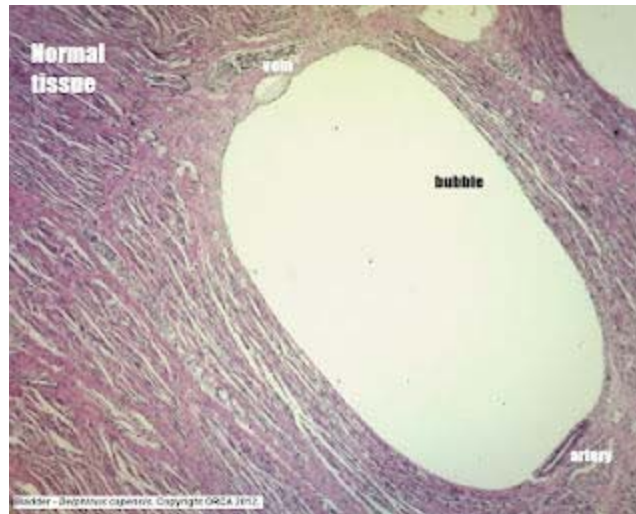Blue Voice

Hardy Jones of Blue Voice and Dr. Yaipen Llanos of ORCA examine a dead baby dolphin in Peru.



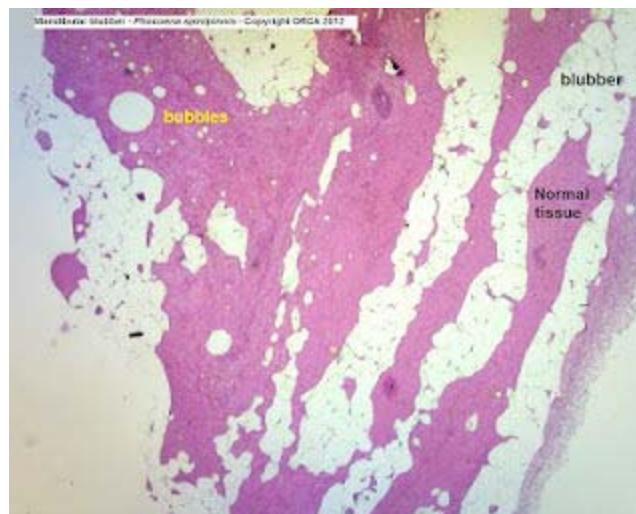
Blue Voice

Bubbles replaced normal tissue in the dolphin's liver.



Blue Voice

A large bubble is compressing a vein and artery in this dolphin's bladder.



Blue Voice

The jaw blubber of this baby porpoise is spread by bubbles. The blood vessels show congestion and hemorrhage.

[Necropsies](#) were performed on site. Macroscopic findings include: hemorrhagic lesions in the middle including the acoustic chamber, fractures in the periotic bones, bubbles in blood filling liver and kidneys (animals were diving, so the main organs were congested), lesion in the lungs compatible with pulmonary emphysema, sponge-like liver. So far we have 12 periotic samples from

different animals, all with different degree of fractures and 80% of them with fracture in the right periotic bones, compatible with acoustic impact and decompression syndrome.

In a February stranding in the same region of Peru, Dr. Llanos found that:

10 of the 17 animals found dead had broken periotic bones, that is, due to acoustic impact. The source of the impact was from the right side of the pod, since hemorrhagic internal ear was found in the right side of the stranded animals.

We know that the use of dynamite is common among fishermen, and that fishermen are taking the meat of the stranded dolphins. This could be the cause of death of the animals...however, the signs do not correspond to that of explosive impact in their bodies. We talked today with people from the oil company and they say they haven't performed any seismic exploration in the area this month. However, here in Peru these companies don't need to do the seismic assessment themselves.

*Update 5/18/12 : Dynamite has been ruled out as a possible cause (via Hardy Jones),*

To compare with some of the stranded dolphins Dr. Llanos examined the remains of healthy dolphins that had been stabbed at sea and eaten by the local fishermen and found "intact periotic (ear) bones, (with no fractures), so it was a good "control" sample to compare with previously collected (and fractured) ones."

Hardy Jones explained to Digital Journal that "traveling to and within Peru is expensive and testing samples from the dead dolphins is very costly, yet highly important." [Blue Voice](#) and Dr. Llanos ([ORCA](#)) will continue to investigate the mortality event, and will post updates.